

Cardiologic Abnormalities in Noonan Syndrome: Phenotypic Diagnosis and Echocardiographic Assessment of 118 Patients

MICHAEL BURCH, MB, MRCP,* MICHAEL SHARLAND, MB, MRCP,
ELLIOT SHINEBOURNE, MD, FRCP,* GILLIAN SMITH, BSc,
MICHAEL PATTON, MD, FRCP, WILLIAM McKENNA, MD, FACC

London, England, United Kingdom

Objectives. The purpose of this study was to determine the incidence of cardiologic abnormalities in Noonan syndrome.

Background. The incidence of cardiac abnormalities in Noonan syndrome remains unknown, largely because of such difficulties as assembling a substantial cohort, ensuring a correct phenotypic diagnosis and providing accurate definitions of the most frequent abnormalities—pulmonary stenosis and left ventricular hypertrophy.

Methods. A cohort of 145 patients was assembled, and before cardiologic assessment two independent geneticists scrutinized the phenotype. The diagnosis was confirmed in 118 patients, and they were studied by two-dimensional and Doppler echocardiography.

Results. A dysplastic pulmonary valve was present in eight patients (7%) and was associated with significant stenosis in six (75%) of the eight. Significant stenosis was present in 22 (20%) of

110 patients without dysplasia. Left ventricular hypertrophy was present in 29 patients (25%) without significant pulmonary stenosis. Localized anterior septal hypertrophy was the most common pattern in 12 (41%) of 29 patients. Diffuse hypertrophy involving the entire septum and the free wall was present in nine patients (31%) and was severe (>1.7 cm) in five. Other abnormalities included secundum atrial septal defects (10%).

Conclusions. The high incidence of cardiac abnormalities suggests that echocardiographic and Doppler evaluation of patients with the Noonan phenotype is important because it will aid in genetic counseling and in the assessment of the natural history of—and, ultimately, identification of the gene(s) responsible for—Noonan syndrome.

(*J Am Coll Cardiol* 1993;22:1189-92)

Previous reviews have suggested that the incidence of Noonan syndrome is between 1 in 1,000 and in 1 in 2,000 of the population (1,2), making it the most common syndrome associated with congenital heart disease after Down syndrome. Cardiac abnormalities are often associated with Noonan syndrome (3-6); however, the precise incidence is uncertain. We therefore assembled a large cohort who had careful assessment of the phenotype and studied them using two-dimensional and Doppler echocardiography.

Methods

Study patients. An initial cohort of 145 patients with the Noonan phenotype was studied. Patients were ascertained with the help of the Noonan Syndrome Society, United Kingdom, using a questionnaire designed to exclude cardiologic bias.

From the Departments of Genetics and Cardiological Sciences, St. Georges Hospital Medical School and *the Royal Brompton National Heart and Lung Hospital, London, England, United Kingdom.

Manuscript received November 12, 1992; revised manuscript received April 12, 1993, accepted April 16, 1993.

Address for correspondence: William McKenna, MD, Department of Cardiological Sciences, St. Georges Medical School, Blackshaw Lane, London SW17, England, United Kingdom.

The diagnosis of the Noonan phenotype was based on the presence of the typical facial features, according to previously published criteria (2,7,8).

Echocardiography. The assessment of hypertrophy was performed using established methodology (9,10). Briefly, the left ventricle was examined at end-diastole in the parasternal short-axis view at the mitral valve and papillary muscle levels and was then divided into quadrants for measurement. Apical views were assessed in the anterior and posterior positions. Systolic anterior motion of the mitral valve was diagnosed from M mode recordings. The left ventricular outflow tract gradient was assessed from the apical five-chamber and suprasternal views using pulsed and continuous wave Doppler echocardiography. The right ventricle was assessed for hypertrophy, again using established methodology (11,12). Measurements were taken of the right ventricular free wall in the parasternal long-axis, parasternal outlet, parasternal inlet and subcostal views.

The pulmonary valve was assessed using two-dimensional echocardiography. Pulmonary valve dysplasia was diagnosed when the pulmonary valve diameter was less than the normal mean (13) and there was asymmetric thickening of the valve cusps with limited cusp movement (14,15). Doppler studies of the pulmonary valve were performed in the parasternal short-axis view using color, pulsed and steerable

continuous wave Doppler ultrasound (16,17). Right ventricular outflow velocity was assessed by Doppler study before pulmonary artery flow velocity to determine any significant subvalvular obstruction (18). Pulmonary regurgitation was assessed according to previously published methodology (19).

The diagnosis of left ventricular hypertrophy was made when wall thickness exceeded 2 SD for an age-matched control group. The definition of hypertrophy in Noonan syndrome is complicated by the frequent association of pulmonary stenosis, which may result in septal hypertrophy and mimic hypertrophic cardiomyopathy (20). Therefore any patient with septal hypertrophy and pulmonary artery Doppler velocity >200 cm/s (arbitrarily taken as that velocity below which right ventricular hypertrophy would be unlikely) was excluded from calculations of the incidence of left ventricular hypertrophy. Right ventricular hypertrophy was defined as a two-dimensional echocardiographic end-diastolic wall thickness >2 SD from age-related normal mean values.

Significant pulmonary stenosis was defined as a pulmonary artery Doppler velocity >300 cm/s, previously taken to indicate significant stenosis (21), or previous intervention (surgical valvotomy or balloon valvuloplasty). Abnormal pulmonary artery Doppler velocity was defined as a velocity >2 SD from the mean value of the normal, control population.

The control group was determined specifically for this study. Analysis of echocardiograms was performed without knowledge of the phenotypic diagnosis. Statistical analysis was performed using a *t* test. Significance was assumed at the 5% level. Results are expressed as mean value \pm SD.

Results

Patient selection. From the 145 patients evaluated by the clinical geneticists, 118 (65 male, 53 female patients aged 1 week to 41 years [mean 10 years]) fulfilled the criteria for the phenotypic diagnosis of Noonan syndrome.

Cardiac Abnormalities

Pulmonary stenosis. Dysplastic valves. The pulmonary valve was dysplastic in eight patients (7%) and was defined as significantly stenotic in six (75%) of the eight. Intervention had been undertaken in three patients (two had surgical valvotomy; one had balloon valvuloplasty). A systolic velocity <300 cm/s with moderate pulmonary regurgitation was revealed in both surgical cases. Conversely, a systolic velocity >300 cm/s without regurgitation was found in the child who had undergone balloon valvuloplasty. All Doppler velocities in the patients who did not undergo surgery were >2 SD from our normal mean value (180 cm/s).

Nondysplastic valves. Significant stenosis in nondysplastic pulmonary valves was present in 22 (20%) of 110 patients. Intervention was undertaken in 17 patients (15 had surgical

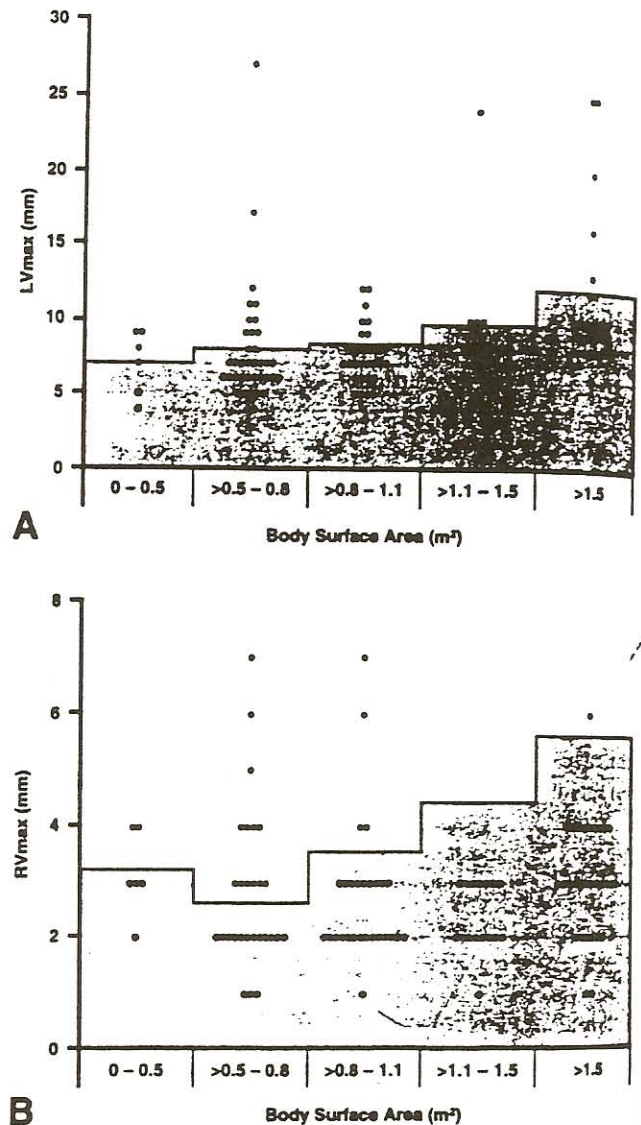


Figure 1. Body surface area versus (A) maximal left ventricular wall thickness at end-diastole (LVmax) and (B) maximal right ventricular wall thickness at end-diastole (RVmax). Shaded areas = values <95 th percentile for normal subjects.

treatment; two had balloon valvuloplasty). Of these the systolic gradient was >300 cm/s in 1 patient (after surgery), and pulmonary regurgitation was moderate in 10 and mild in 6. A pulmonary artery Doppler flow velocity >2 SD from our normal mean value was found in 48 other patients (44%); however, a murmur was audible in only 22 (46%).

Ventricular hypertrophy. Wall thicknesses in relation to that of age-matched control subjects are shown in Figure 1. Overall left ventricular hypertrophy was present in 29 (25%) of 118 patients, and in this group there was a positive correlation with right ventricular wall thickness ($r = 0.7$, $p < 0.05$). Right ventricular hypertrophy was present in 20 (17%) of 118 patients, and significant pulmonary stenosis was present in 7 (35%) of the 20 and left ventricular hypertrophy in 8 (40%). Isolated septal hypertrophy was present in 140

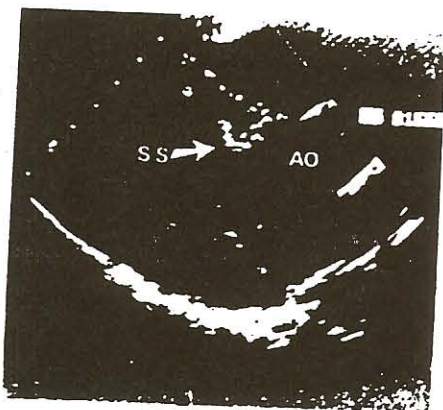


Figure 2. Subaortic shelf in a 12-year old boy with Noonan syndrome. Two-dimensional echocardiogram in the parasternal long-axis view. AO = aorta; SS = subaortic shelf.

additional patients who had pulmonary artery Doppler flow velocity >200 cm/s. However, they were not considered to have left ventricular hypertrophy for the reasons defined earlier (see Echocardiography).

Maximal left ventricular wall thickness, in the 29 patients with hypertrophy, was at the upper anterior septum in 26 patients, the free wall in 2 and the lower anterior septum in 1. Hypertrophy involved the anterior septum in all 29 patients. In 12 patients (41%) it was confined to the anterior septum, and in 5 of these 12 it was a localized upper septal bulge (Fig. 2). In eight patients (28%) the posterior septum was also involved. An additional nine patients (31%) had diffuse hypertrophy involving the anteroseptal and posteroseptal regions and the free wall. Severe hypertrophy was present in five of the latter nine patients, and maximal wall thickness ranged from 1.7 to 2.7 cm (mean 2.3 ± 0.4) (Fig. 3). Systolic anterior motion of the mitral valve was present in all five patients. It was complete, with septal and anterior leaflet contact (22), in one patient who had a gradient of 64 mm Hg, but the gradient was <36 mm Hg in the other four. None of

Figure 3. Diffuse left ventricular hypertrophy in a 12-year old girl with Noonan syndrome. Two-dimensional echocardiogram in the parasternal short-axis view. AS = anterior septum; FW = free wall; PS = posterior septum; PW = posterior wall.

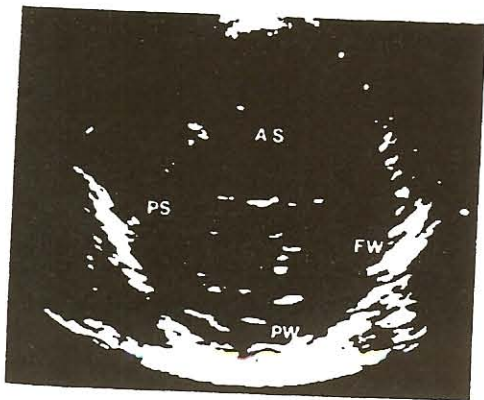


Table 1. Other Cardiac Abnormalities

Diagnosis	No.	%
Secundum atrial septal defect	12	9.8
Ventricular septal defect	3	0.8
Primum atrial septal defect	3	2.5
Tetralogy of Fallot	1	0.8
Complete atrioventricular septal defect	1	0.8
Aortic stenosis	1	0.8
Supravalvular aortic stenosis	1	0.8
Bicuspid aortic valve	1	0.8
Patent ductus arteriosus	1	0.8

the patients with ventricular hypertrophy had an affected first-degree relative on family screening, nor was there a family history of sudden death in early adult life. In addition, there was no history of syncope, and only one patient (an infant) had evidence of cardiac failure.

Other Cardiac Abnormalities

Other cardiac abnormalities were common (Table 1). All but three of the septal defects had been corrected.

None of the three patients with aortic valve anomalies had left ventricular hypertrophy. A supravalvular aortic ridge has not been previously described in Noonan syndrome.

Discussion

To overcome the inherent difficulties of assessing the incidence of cardiac problems in Noonan syndrome, this study required a high level of genetic input. Cardiologic bias was removed by not specifically drawing from cardiac clinics. Furthermore, the large cohort enabled an accurate assessment to be made. Cardiac abnormalities were common, particularly pulmonary stenosis and ventricular hypertrophy. Some of the diagnoses reported in Noonan syndrome, however, such as disorders of the aortic valve sinuses and root (23,24), were not seen, in contrast to the Marfan or Turner syndrome, where aortic valve and aortic root problems are more common (25,26).

Pulmonary stenosis. Only a minority of patients in our study had the dysplastic valves thought typical of Noonan syndrome. However, those with dysplastic valves were more likely to need intervention and were less likely to have a satisfactory result, which is consistent with previous reports highlighting the difficulties of dilating dysplastic valves (14,27,28). Thus, the outcome of intervention is more likely to reflect the presence or absence of dysplasia rather than Noonan syndrome as such.

Ventricular hypertrophy. It is uncertain whether the unexplained left ventricular hypertrophy seen in 25% of patients in this study represents hypertrophic cardiomyopathy. We recently reported histologic similarity between the hypertrophy of Noonan syndrome and hypertrophic cardiomy-

opathy (29). The latter is a genetically heterogeneous disease, approximately 50% of patients having a missense mutation in the gene encoding beta-cardiac heavy chain myosin (30). The echocardiographic morphology has been well described elsewhere (31) and, although similar, it appears subtly different to that in patients with Noonan syndrome. In this study hypertrophy was often confined to the upper anterior septum and was only rarely severe and diffuse, which is the converse of the appearance of hypertrophic cardiomyopathy. (The electrocardiogram was not used, and although it can be helpful in diagnosing hypertrophy [32], it is less specific than echocardiography.) The clinical course of the two diseases is also dissimilar. To our knowledge, sudden death has not been reported in Noonan syndrome, although it is common in hypertrophic cardiomyopathy (33,34). Given the recent mapping of a gene for familial hypertrophic cardiomyopathy to chromosome 14q1 (35), linkage studies in Noonan syndrome are feasible and would be the final arbiter of whether the two conditions share a common etiology and prognosis.

Conclusions. The high incidence of cardiac abnormalities, particularly left ventricular hypertrophy, pulmonary stenosis, and secundum atrial septal defects, in the present series of patients studied here confirms the importance of cardiologic evaluation in the phenotypic assessment of patients with Noonan syndrome.

References

- Mendez HMM, Opitz JM. Noonan syndrome: a review. *Am J Med Genet* 1985;21:493-506.
- Allanson JE. Noonan syndrome. *J Med Genet* 1987;24:9-13.
- Noonan JA, Ehmke DA. Associated non-cardiac malformations in children with congenital heart disease. *J Pediatr* 1963;63:468-70.
- Noonan JA. Hypertelorism with Turner phenotype. A new syndrome with associated congenital heart disease. *Am J Dis Child* 1968;116:373-80.
- Phornphutkul C, Rosenthal A, Nadas AS. Cardiomyopathy in Noonan syndrome. *Br Heart J* 1973;35:99-102.
- Hirsch HD, Gelband H, Garcia O, Gottlieb S, Tamer DM. Rapidly progressive obstructive cardiomyopathy in infants with Noonan syndrome. *Circulation* 1975;52:1161-5.
- Sharland M, Morgan M, Smith G, Burch M, Patton M. Genetic counseling in Noonan syndrome. *Am J Med Genet* 1993;45:437-40.
- Sharland M, Morgan M, Patton MA. Photoanthropometric study of facial growth in Noonan syndrome. *Am J Med Genet* 1993;45:430-6.
- Maron BJ, Gottdiener JS, Bonow RD, Epstein SE. Hypertrophic cardiomyopathy with unusual locations of left ventricular hypertrophy undetectable by M mode echocardiography. Identification by wide angle two-dimensional echocardiography. *Circulation* 1981;63:409-18.
- Shapiro LM, McKenna WJ. Distribution of left ventricular hypertrophy in hypertrophic cardiomyopathy: a two-dimensional echocardiographic study. *J Am Coll Cardiol* 1983;2:437-44.
- Foale R, Nihoyannopoulos P, McKenna W, et al. Echocardiographic measurement of the normal adult right ventricle. *Br Heart J* 1986;56:33-44.
- McKenna WJ, Kleinebenne A, Nihoyannopoulos P, Foale R. Echocardiographic measurement of right ventricular wall thickness in hypertrophic cardiomyopathy: relation to clinical and prognostic features. *J Am Coll Cardiol* 1988;11:351-8.
- Ichida F, Aubert A, Denet B, Dumoulin M, van der Haumart L. Cross sectional echocardiographic assessment of great artery diameters in infants and children. *Br Heart J* 1987;58:627-34.
- Marantz PM, Huhta JC, Mullins CE, et al. Results of balloon valvuloplasty in typical and dysplastic pulmonary valve stenosis: Doppler echocardiographic follow-up. *J Am Coll Cardiol* 1988;12:476-9.
- Schmeeweiss A, Blieden LC, Shem-Tov A, Goor D, Milo S, Neufeld HN. Diagnostic angiographic criteria in dysplastic stenotic pulmonary valve. *Am Heart J* 1983;106:761-2.
- Lima CO, Sahn DJ, Valdez Cruz LM, et al. Non-invasive prediction of transvalvular pressure gradients in patients with pulmonary stenosis by quantitative two-dimensional echocardiographic Doppler studies. *Circulation* 1983;67:866-70.
- Houston AB, Sheldon CS, Simpson IA, Doig WB, Coleman EN. The severity of pulmonary valve or artery obstruction in children estimated by Doppler ultrasound. *Eur Heart J* 1985;6:786-90.
- Houston AB, Simpson IA, Sheldon CD, Doig WB, Coleman EN. Doppler ultrasound in the estimation of the severity of pulmonary infundibular stenosis in infants and children. *Br Heart J* 1986;55:381-5.
- Masura J, Burch M, Deanfield JE, Sullivan ID. Five-year follow-up after balloon pulmonary valvotomy. *J Am Coll Cardiol* 1993;21:132-7.
- Maron BJ, Clark CE, Henry WL, et al. Prevalence and characteristics of disproportionate ventricular septal thickening in patients with acquired or congenital heart disease. *Circulation* 1977;55:489-96.
- McCordle BW, Kan JS. Long term results after balloon pulmonary valvuloplasty. *Circulation* 1991;83:1915-22.
- Gilbert BW, Pollick C, Adelman AG, Wigle ED. Hypertrophic cardiomyopathy: subclassification by M mode echocardiography. *Am J Cardiol* 1980;45:861-72.
- Morgan JM, Coupe MO, Honey M, Miller GAH. Aneurysms of the sinuses of Valsalva in Noonan's syndrome. *Eur Heart J* 1989;10:190-3.
- Shacter N, Perloff JK, Mulder DG. Aortic dissection in Noonan's syndrome. *Am J Cardiol* 1984;54:464-5.
- Van der Hauwert LG, Fryns JP, Dumoulin M, Logghe N. Cardiovascular malformations in Turner's and Noonan's syndromes. *Br Heart J* 1978;40:500-9.
- Roberts WC, Honig HS. The spectrum of cardiovascular disease in the Marfan syndrome: a clinico-morphologic study of 18 necropsy patients and comparison to 151 previously reported necropsy patients. *Am Heart J* 1982;104:115-35.
- Sullivan ID, Robinson PJ, Macartney FJ, et al. Percutaneous balloon valvuloplasty for pulmonary valve stenosis in infants and children. *Br Heart J* 1985;54:435-41.
- Musewe NN, Robertson MA, Benson LN, et al. The dysplastic pulmonary valve. Echocardiographic features and results of balloon dilatation. *Br Heart J* 1987;57:364-70.
- Burch M, Mann J, Sharland M, Shinebourne E, Patten M, McKenna W. Myocardial disarray in Noonan syndrome. *Br Heart J* 1992;68:586-8.
- Rosenzweig A, Watkins H, Hwang DS, et al. Preclinical diagnosis of familial hypertrophic cardiomyopathy by genetic analysis of blood lymphocytes. *N Engl J Med* 1992;325:1753-60.
- Maron BJ, Gottdiener JS, Epstein SE. Patterns and significance of distribution of left ventricular hypertrophy in hypertrophic cardiomyopathy. *Am J Cardiol* 1981;48:418-28.
- Savage DD, Siedes SF, Clark CE, et al. Electrocardiographic findings in patients with obstructive and non-obstructive hypertrophic cardiomyopathy. *Circulation* 1978;58:402-8.
- McKenna WJ, Deanfield JE. Hypertrophic cardiomyopathy: an important cause of sudden death. *Arch Dis Child* 1984;59:971-5.
- Maron BJ, Henry WL, Clark CE, Redwood DR, Roberts WC, Epstein JE. Asymmetric septal hypertrophy in childhood. *Circulation* 1976;53:9-14.
- Jarcho JA, McKenna W, Pare JAP, et al. Mapping a gene for familial hypertrophic cardiomyopathy to chromosome 14q 1. *N Engl J Med* 1989;321:1372-8.